

LIFE THREATENING SKIN RASHES

Authors

G. Shanthi Priya

Department of Pharmacology
Gokaraju Rangaraju College of Pharmacy
Bachupally, Hyderabad, India
gshanthipriya00@gmail.com

Sneha Chukkala

Department of Pharmacology
Gokaraju Rangaraju College of Pharmacy
Bachupally, Hyderabad, India

I. INTRODUCTION

Dermatology is the field of medicine that deals with skin conditions. It is a medical and surgical specialty. A dermatologist is a type of health care profession who treats skin, hair, nail, and aesthetic concerns. The skin is largest organ in our body, it acts as a barrier to protect our internal organs from damage and pathogens. Furthermore, it is an excellent predictor of the overall health of the body, making dermatology vital for the detection and treatment of a wide range of medical illnesses.

Some of the most common dermatologic conditions include:

- Pustules : Pimples on the skin induced by exocrine glands irritation.
- Tetter : Skin irritation causes red, puffy and sore skin.
- Eczema : Rough and inflamed skin
- Psoriasis : Itchy, red, scaly patches on skin
- Warts : A virus produces a hardening of the skin.
- Cold sore : Herpes simplex virus causes an inflamed blister around the lips.

Dermatological emergencies rare, but if they are not identified and treated right away, they might result in fatal complications.

II. SKIN DISEASES

An intensive care unit is necessary for the treatment of several skin disorders. The most dangerous skin problems are listed here.

- 1. Necrotising fasciitis:** Necrotizing fasciitis is a subtype of destructive skin and flexible tissue infections that induce decrease of muscular fascia and hypodermis. Fascial plane, where this illness often spreads, has a weak blood supply. As a result, the underlying tissues are initially untouched, which may delay detection and healing treatment. Infectious process can progress quickly, infecting the fascia and peri-fascial planes as well as the skin, soft tissue, and muscle directly above and below [1,2,3].

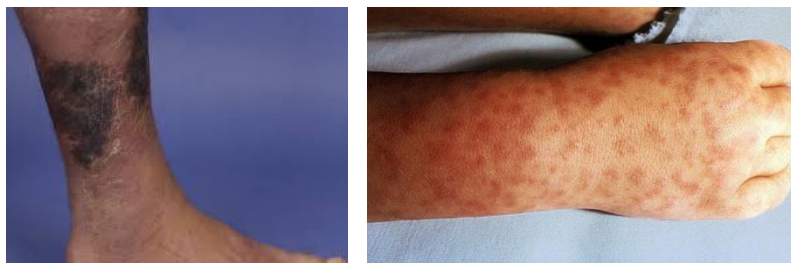


Figure 1: Necrotising Fasciitis

Aetiology: Necrotizing fasciitis is typically an acute disease that spreads quickly over several days. It is a clear indication of bacterial infection introduced through small rupture on skin in around 80% of all cases. Gram-positive cocci, notably strains of Golden staph and true bacteria, causes majority of single-site infections. Furthermore, gram-negative and anaerobic participation leads to polymicrobial infections [4,5].

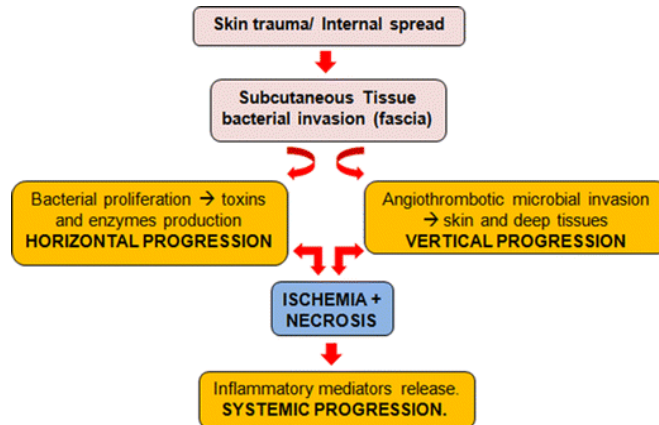


Figure 2: Pathophysiology of Necrotizing fasciitis

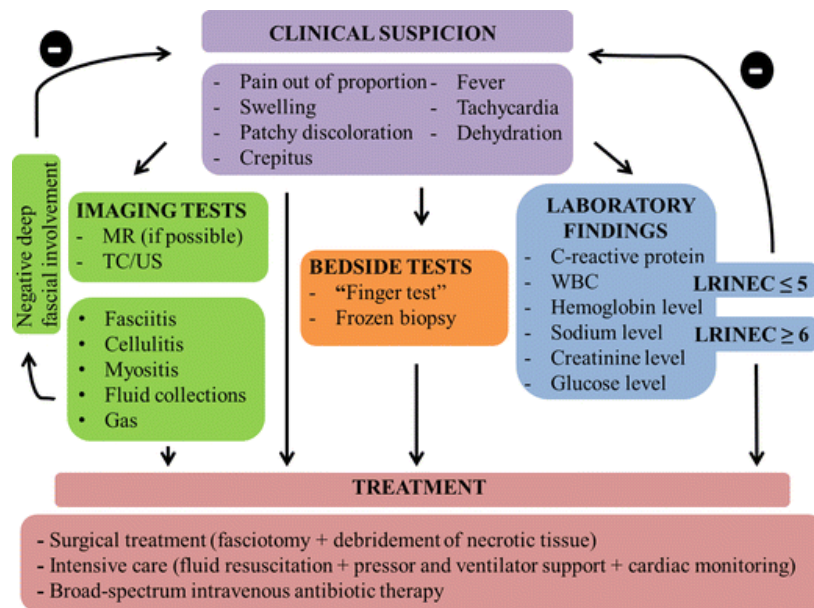
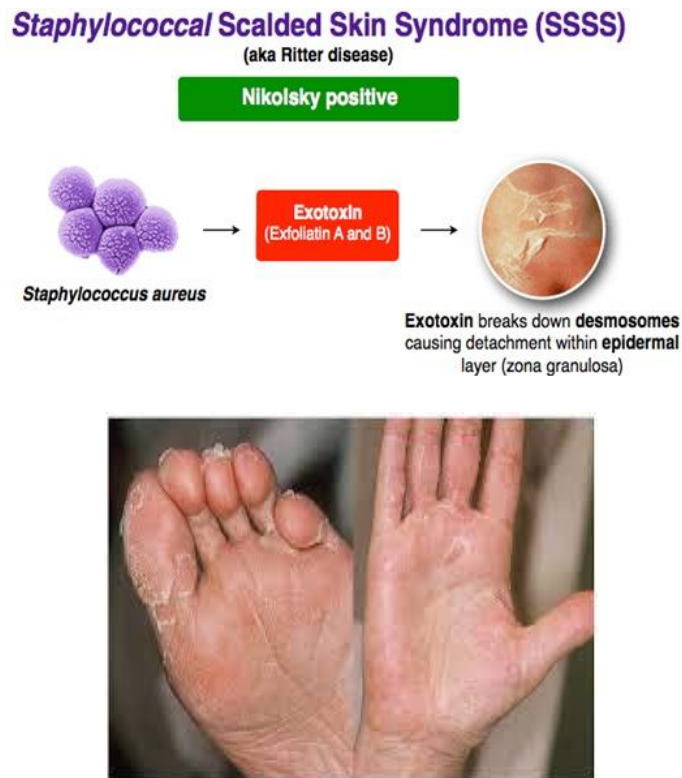


Figure 3: Diagnosis of Necrotizing fasciitis

Outcomes: Necrotizing fasciitis is dangerous, with a fatality fluctuating from 30 to 90%. Patients infected with specific streptococcal strains have the worst prognosis. Other elements are renal failure, respiratory pain, ARDs, and loss of consciousness. Patients who undergo rigorous grafting and broad-spectrum antibiotics as soon as possible have the best chance of survival. Even after treatment, people with the illness often have shorter lifetimes than age-matched controls [6].

- Staphylococcal scalded skin syndrome:** Golden staph causes the skin infection like staphylococcal scalded skin syndrome (SSSS). As a result of the bacterium's exfoliative toxin, the skin's outer layers blister and peel.



Bacteria enter the body through a skin break. The toxin produced by the bacterium inhibits the skin's ability to stay together. The separation of the upper layer of skin from deeper layers causes the characteristic peeling of SSSS. When the poison enters the bloodstream, it may cause a response all over the skin. Young children, particularly newborns, are more vulnerable because they lack immune systems and kidneys that can clear toxins from the body.

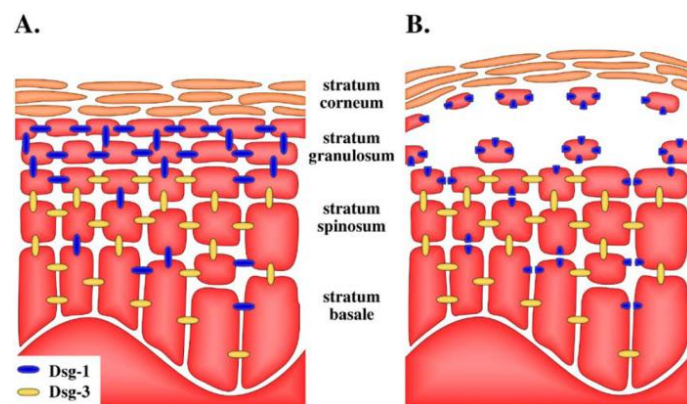


Figure 4: Scalded skin syndrome pathophysiology

The peeling toxin-induced cuts at the stratum granulosum is explained by differential distribution of desmoglein isoforms in the epidermis [8]. Desmoglein distribution in (A) healthy skin and (B) skin that has been subjected to an exfoliative toxin is shown schematically. Desmoglein 3 compensates for exfoliative toxin-mediated

hydrolysis of desmoglein 1 (Dsg-1) in all layers other than stratum granulosum (Dsg-3). The absence of Dsg-3 in stratum granulosum describes why cells detached and the epidermal layers separated when Dsg-1 is hydrolyzed.

- **Management of SSSS:** As a dermatological emergency, SSSS calls for immediate hospitalisation and care. This typically entails:
- **First-line:** a penicillinase-resistant, anti-staphylococcal antibiotic such as flucloxacillin.
- **Other options include:** ceftriaxone, clarithromycin (for penicillin-allergy), cefazolin, nafcillin, or oxacillin.
- **Methicillin resistance (MRSA) infection:** vancomycin [7].

3. DRESS Syndrome: The "drug rash with eosinophilia and systemic symptoms" (DRESS) syndrome refers to unique, serious, distinctive reaction to medications. It is characterized by lengthy dormancy phase. It is followed by variety of mild-to-severe systemic manifestations and clinical symptoms, including fever, rash, lymphadenopathy, eosinophilia, and lymphadenopathy. It is a term for a painful reaction is used to describe an allergic reaction with a 10% fatality.

Patients typically experience fever in early phase of disease, which is followed by rashes. More prevalent than a moderate exanthem or considerable intense and itching, macular erythema with papules, pustules or vesicles. Lymphadenopathy, hepatitis, pericarditis, interstitial nephritis or pneumonitis are common manifestations of systemic involvement. Auto-immunity could arise as a result of DRESS. Genetic factors play a role as well. Individuals for those who have first-degree relatives with a history of DRESS are at a 25% increased risk [8].

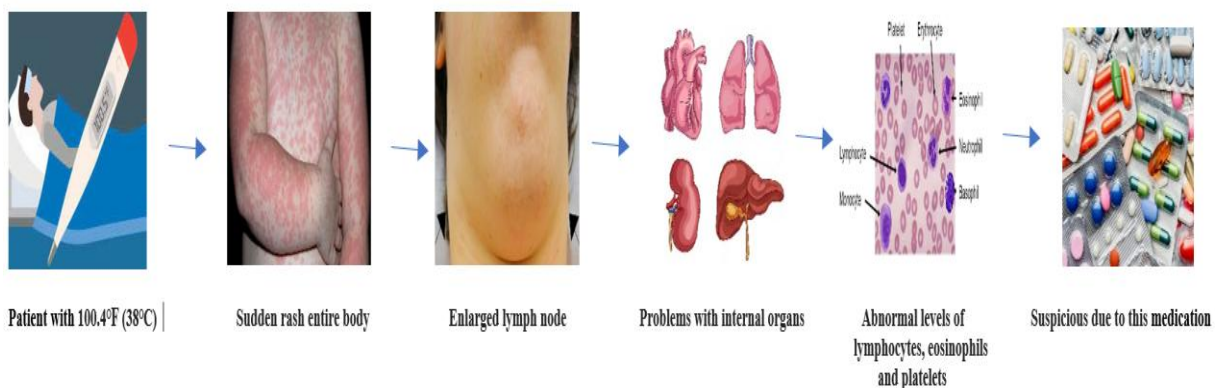


Figure 5: Pathophysiology of DRESS

Drugs that lead to DRESS syndrome are Anti-seizure drugs, such as lamotrigine, carbamazepine, phenobarbital, Allopurinol, Antibiotics, minocycline, vancomycin, Sulfasalazine drugs used to treat autoimmune diseases like rheumatoid arthritis and ulcerative colitis, NSAID like ibuprofen and celecoxib and HIV medicines [9].

Management of DRESS: In order to treat DRESS, systemic corticosteroids have been used.

- 4. Rocky mountain spotted fever:** Rocky Mountain Spotted Fever is caused by obligatory intracellular coccobacillus *Rickettsia*. Ticks, either *Dermacentor andersoni* like the Rocky Mountain wood tick in the west or *Dermacentor variabilis* like the American dog tick in the east spreads the disease. Although the disease was found in Idaho and Montana, the bulk of cases are concentrated in United States' south central and southern areas, making the term "Rocky Mountain spotted fever" inaccurate from the epidemiologic standpoint. The sickness has been reported in almost every state [10].

Since RMSF is a seasonal illness, the majority of cases take place in the spring and summer, when tick activity is at its peak and human-tick contact is most common. The most commonly impacted groups include farmers, kids, and outdoor recreationists. A 5 to 25% mortality rate is possible. The prognosis is influenced by diagnosis of the illness and beginning of the proper antibiotic therapy.

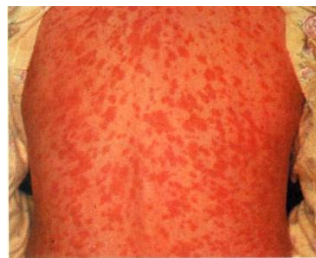

Figure 6: Symptoms of RMSF

Laboratory tests won't help with the diagnosis of RMSF during the acute stage. Recognition is solely dependent on comprehension of the clinical and epidemiologic symptoms, including fever, headache, and rash in people who are in contact with ticks. It is best to look for signs of recent outdoor activity, travel to an endemic region, or a history of tick bites. Unfortunately, only 60 to 70% of patients initially examined the characteristic of fever, rash, and past tick bites.

Management of RMSF: The cornerstone treatment is doxycycline (administered intravenously or orally). A pregnant woman or a small child may use chloramphenicol. For seriously ill patients, supportive care may be required. Importantly, RMSF cannot be treated with normal broad-spectrum antibiotics [11].

- 5. Toxic epidermal necrolysis:** Extensive exfoliating the epidermis and mucous membrane is a feature of toxic epidermal necrolysis (TEN), a potentially fatal illness that can cause sepsis and death [12]. The disease process that defines Steven-Johnson Syndrome (SJS) is the same that is seen in drug-induced epidermolysis. The degree of skin separation has the greatest difference [13].

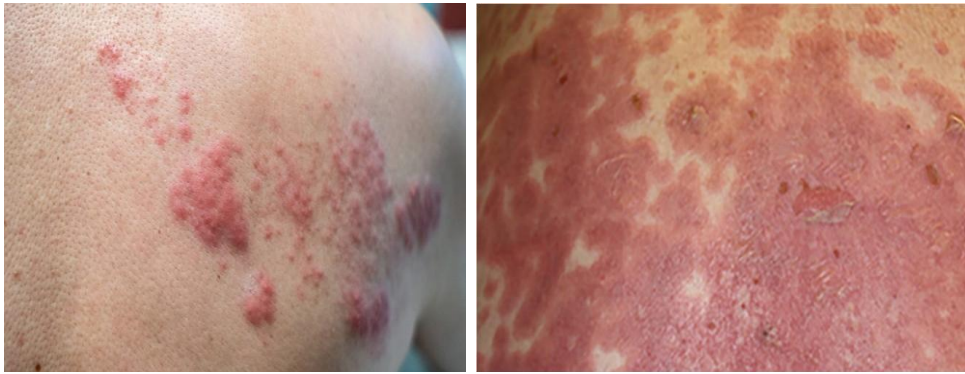

Figure 7: Toxic Epidermal Necrolysis

Etiology: Lamotrigine, phenytoin, nevirapine, phenobarbital, sulfasalazine and NSAIDs are medication with a high risk of TEN [14,15].

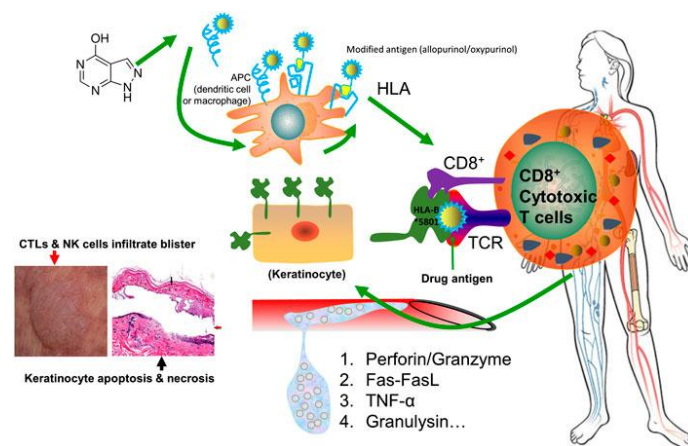


Figure 8: Toxic Epidermal Necrolysis Pathophysiology

Diagnosis: Serum granulysin measurements made in the early days drug eruption may be predicted the development of this disease.

- Skin biopsy is necessary to verify the clinical diagnosis and exclude out other generalised rashes with blisters, such as staphylococcal scalded skin syndrome, as well as other rashes.
- Histopathology reveals keratinocyte necrosis, epidermal/epithelial necrosis and mild inflammation. Because the direct immunofluorescence test on the skin sample is negative, it is clear that condition is not caused by a buildup of antibodies on the skin.
- Blood tests are required to detect abnormalities, assess prognostic factors, and ensure enough hydration and nutrition, but they do not aid in diagnosis. Abnormalities may include:
 - Anaemia most often occurs (reduced haemoglobin).
 - Leucopenia (low white blood cell counts), particularly lymphopenia (low lymphocyte counts), is extremely common (90%)
 - Neutropenia, or decreased neutrophils, is a symptom that the outcome is poor.

- There is no eosinophilia (increased eosinophil count) or atypical lymphocytosis (lymphocytes with unusual appearances).
- 30% of people have mildly elevated liver enzymes, and 10% have observable hepatitis.
- About 50% of people have protein leakage in urine. The majority of people experience some changes in renal function.

Investigations are being done on *in-vitro* diagnostic techniques for allergies medication, including SJS/TEN. Patch testing is not recommended because it rarely identifies the cause of SJS/TEN [16,17].

REFERENCES

- [1] Kim YH, Ha JH, Kim JT, Kim SW. Managing necrotising fasciitis to reduce mortality and increase limb salvage. *J Wound Care*. 2018 Sep 01;27(Sup9a): S20-S27.
- [2] Lange JH, Cegolon L. Comment on: Early clinical manifestations of vibrio necrotising fasciitis. *Singapore Med J*. 2018 Aug; 59(8):449.
- [3] Heijkoop B, Parker N, Spornat D. Fournier's gangrene: not as lethal as previously thought? A case series. *ANZ J Surg*. 2019 Apr;89(4):350-352
- [4] Erichsen Andersson A, Egerod I, Knudsen VE, Fagerdahl AM. Signs, symptoms and diagnosis of necrotizing fasciitis experienced by survivors and family: a qualitative Nordic multi-center study. *BMC Infect Dis*. 2018 Aug 28; 18(1):429.
- [5] Khalid M, Junejo S, Mir F. Invasive Community Acquired Methicillin-Resistant Staphylococcal Aureus (CA-MRSA) Infections in Children. *J Coll Physicians Surg Pak*. 2018 Sep;28(9): S174-S177
- [6] Gawaziuk JP, Strazar R, Cristall N, Logsetty S. Factors predicting health-related quality of life following necrotizing fasciitis. *J Plast Reconstr Aesthet Surg*. 2018 Jun;71(6):857-862.
- [7] Arnemann, J.; Sullivan, K.H.; Magee, A.I.; King, I.A.; Buxton, R.S. Stratification-related expression of isoforms of the desmosomal cadherins in human epidermis. *J. Cell Sci*. 1993, 104(Pt 3), 741–750.
- [8] Seth D et al (2008) DRESS syndrome: A practical approach for primary care practitioners. *Clinical Paediatrics*. 47(9):947-52.
- [9] American Academy of Allergy, Asthma & Immunology. (2020). Medications and drug allergic reactions.
- [10] Klirkland KB, Wilkinson WE, Sexton DJ. Therapeutic delay and mortality in cases of Rocky Mountain spotted fever. *Clin Infect Dis*. 1995; 20: 1118-1121
- [11] Spach DH, Liles WC, Campbell GL, Quick RE, Anderson Jr, DE, FriUche TR. Tick-borne diseases in the United States. *N Engl J Med*. 1993; 329: 936-947
- [12] LYELL A. Toxic epidermal necrolysis: an eruption resembling scalding of the skin. *Br J Dermatol*. 1956 Nov;68(11):355-61.
- [13] Bastuji-Garin S, Rzany B, Stern RS, Shear NH, Naldi L, Roujeau JC. Clinical classification of cases of toxic epidermal necrolysis, Stevens-Johnson syndrome, and erythema multiforme. *Arch Dermatol*. 1993 Jan;129(1):92-6.
- [14] Pejčić AV. Stevens-Johnson syndrome and toxic epidermal necrolysis associated with the use of macrolide antibiotics: a review of published cases. *Int J Dermatol*. 2021 Jan;60(1):12-24.
- [15] Moshfeghi M, Mandler HD. Ciprofloxacin-induced toxic epidermal necrolysis. *Ann Pharmacother*. 1993 Dec;27(12):1467-9.
- [16] Mockenhaupt M, Viboud C, Dunant A, Naldi L, Halevy S, Bouwes Bavinck JN, Sidoroff A, Schneck J, Roujeau JC, Flahault A. Stevens-Johnson syndrome and toxic epidermal necrolysis: assessment of medication risks with emphasis on recently marketed drugs. The EuroSCAR-study. *J Invest Dermatol*. 2008 Jan;128(1):35-44.